

1,550 nm Erbium-Doped and 1,927 nm Thulium Nonablative Fractional Laser System: Best Practices and Treatment Setting Recommendations

Paul M. Friedman, MD,* Jeffrey S. Dover, MD, FRCPC,† Anne Chapas, MD,‡ Zakia Rahman, MD,§ Edward V. Ross, MD,|| Suzanne L. Kilmer, MD,¶ Wendy E. Roberts, MD,** Pooja Sodha, MD,†† Julie B. Stimmel, PhD,‡‡ Mary Beth C. Moncrief, PhD,‡‡ and Jill S. Waibel, MD§§

BACKGROUND The Fraxel Dual laser system (Solta Medical, Inc., Bothell, WA) contains a 1,550 and 1,927 nm wavelength single handpiece with different indications for each wavelength.

OBJECTIVE To discuss treatment setting recommendations and best practices for select on-label and investigational applications of the 1,550 and 1,927 nm dual laser system.

MATERIALS AND METHODS Eight board-certified dermatologists with 10 or more years of experience with the 1,550 and 1,927 nm laser system completed an online survey about their clinical experience with the system and then participated in a roundtable to share clinical perspectives and best practices for using the laser system.

RESULTS For all Fitzpatrick skin types, treatment recommendations were described for selected approved indications for the 1,550 and 1,927 nm laser system, including both lasers in combination. Treatment recommendations were also reached for investigational applications with the 1,550 nm laser and 1,927 nm laser. Best practices for using the lasers during the treatment session to achieve optimal outcomes and decrease the post-treatment recovery time were compiled.

CONCLUSION The 1,550 and 1,927 nm dual laser system is effective for a wide range of aesthetic and therapeutic applications, on and off the face and across all Fitzpatrick skin types.

Nonablative fractional lasers (NFLs) for facial rejuvenation are midinfrared lasers with wavelengths ranging from 1,320 to 1,940 nm that target water as a chromophore. Fractional laser treatment produces an array of microscopic treatment zones (MTZs) of thermal injury to the skin that induce a dermal wound response without damaging the epidermis.^{1,2}

The Fraxel Dual laser system (Solta Medical, Inc., Bothell, WA), a current generation NFL system, contains a 1,550 and 1,927 nm wavelength single handpiece with different

indications for each wavelength. The 1,550 nm erbium-doped laser is indicated for procedures requiring coagulation of soft tissue, skin resurfacing procedures, and treatment of dyschromia, epidermal lesions (e.g., lentigines and actinic keratoses [AK]), dermal pigmentary disorders (e.g., melasma), periorbital wrinkles, acne scars, and surgical scars. The 1,927 nm thulium laser is indicated for dermatological procedures requiring coagulation of soft tissue (Figure 1) as well as the treatment of AK and dyschromia. The current objective is to delineate best practices for select on-label and investigational applications of the 1,550 and 1,927 nm dual laser system, as identified by a clinical expert roundtable.

Methods

Eight board-certified dermatologists with 10 or more years of experience with the 1,550 and 1,927 nm laser system (Fraxel Dual laser system) completed an online survey about their clinical experience with the system. After survey completion, the same clinicians participated in a roundtable discussion (April 2020) supported by Solta Medical to develop best practices for using the laser system.

Expert Roundtable Recommendations

Current Indications

Surgical and Acne Scars

For surgical scars, when using the 1,550 nm wavelength alone, 4 to 6 treatment sessions every 4 to 6 weeks are recommended using a pulse energy based on the scar depth, with 9% to 23%

From the *Dermatology & Laser Surgery Center, Houston, Texas; †SkinCare Physicians, Chestnut Hill, Massachusetts; ‡Union Square Laser Dermatology, New York, New York; §Stanford Department of Dermatology, Redwood City, California; ||Scripps Clinic, San Diego, California; ¶Laser & Skin Surgery Medical Group, Inc., Sacramento, California; **Generational and Cosmetic Dermatology, Rancho Mirage, California ††Department of Dermatology, George Washington University, Washington, District of Columbia; ‡‡Synchrony Medical Communications, LLC, West Chester, Pennsylvania; §§Miami Dermatology & Laser Institute, Miami, Florida Supported by Solta Medical Inc. P. M. Friedman and Waibel have served on the advisory board for Solta Medical, Inc, and J. S. Dover, A. Chapas, Z. Rahman, E. V. Ross, S.L. Kilmer, W. E. Roberts, and P. Sodha have served as consultants for Solta Medical, Inc.

The authors have indicated no significant interest with commercial supporters.

Address correspondence and reprint requests to: Paul M. Friedman, MD, Dermatology & Laser Surgery Center, 6400 Fannin Street #2720, Houston, TX 77030, or e-mail: drpaul@dermlasersurgery.com

This is an open-access article distributed under the terms of the Creative Commons Attribution-Non Commercial-No Derivatives License 4.0 (CCBY-NC-ND), where it is permissible to download and share the work provided it is properly cited. The work cannot be changed in any way or used commercially without permission from the journal.

<http://dx.doi.org/10.1097/DSS.0000000000003321>

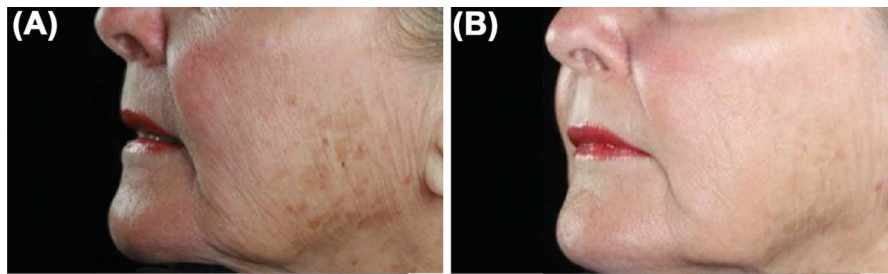


Figure 1. Patient with Fitzpatrick skin type II and photoaging at baseline (A) and 3 months post-treatment (B). She received 3 treatment sessions with 1,927 nm thulium laser (20 mJ; treatment level 9). Courtesy of Paul M. Friedman, MD.

coverage, delivered over 8 passes. For erythematous scars, treatment with a vascular-specific laser is recommended prior to the initiation of 1,550 nm wavelength treatment. Atrophic acne scars (Figure 2), such as shallow boxcar and rolling scars, may respond best to 4 to 6 treatment sessions with the 1,550 nm wavelength every 4 to 8 weeks, with longer intervals for Fitzpatrick skin type (FST) IV to VI. The recommended pulse energy level is 12 to 70 mJ, depending on the acne scar depth, with 8 passes using a treatment level (coverage) of 3 to 8 (9%–23%) for FST I to III and 3 to 7 (9%–20%) for FST IV to VI. Ice pick, deep rolling, and boxcar scars tend to be more challenging to treat because the energy does not penetrate to a depth necessary to treat the scar base or dermal tethering to the subcutis.³ Roundtable participants have observed improved outcomes when treating some types of acne scars with the 1,550 nm laser and minimally invasive interventions (e.g., punch excision or elevation, or subcision immediately before, micro-needling [depth, 1.5–3.0 mm; \pm needle radiofrequency]), which can be performed on the day of 1,550 nm laser treatment or 4 to 6 weeks before or after treatment. In addition, the use of a dermal filler after 1,550 nm laser treatment can enhance results and should be performed 8 to 12 weeks after the last laser treatment, once dermal remodeling has started. Injectable poly-L-lactic acid may be administered 2 to 4 weeks before, the same day as, or at least 2 weeks after 1,550 nm laser treatment. Hypertrophic acne scars should first be treated with vascular laser therapy to soften and minimize the vascularity, thereby reducing the hypertrophic component of the lesion.

Serial treatment with the 1,550 nm laser induces collagen remodeling in the dermis. Energy density levels can be adjusted depending on patient tolerance (recommended total energy delivery, 3–6 kJ per treatment, variable depending on the area treated). For patients with active acne, a 5- to 7-day course of

oral antibiotics is recommended to minimize post-treatment acne flares. In a study of 29 patients with FST I to V and various types of acne scarring, ranging from mild to severe, on the face and back who underwent 2 to 6 treatments with the 1,550 nm laser (energy, 35–40 mJ and treatment settings, 7–10 [coverage, 20%–35%]) at 4-week intervals, 79.3% of patients (23/29) experienced a 50% to 75% improvement from baseline at 1 month after the final treatment.⁴

General Skin Resurfacing and Actinic Keratoses

Treatment settings for general skin resurfacing with the 1,550 nm laser (Table 1) were discussed. Seven of the roundtable participants reported using the 1,927 nm laser for AK. In their experience, treatment with the 1,927 nm laser prevented AK recurrence. For improvement in skin laxity (off-label) and dyschromia, in addition to AK removal, a greater number of treatments would be needed.

In one study, 24 patients predominantly with FST I to II, facial photodamage, and AK underwent up to 4 treatments with the 1,927 nm laser (energy, 5–20 mJ and treatment settings, 5–11 [coverage, 40%–70%]) at 2- to 6-week intervals and experienced an 86.6% reduction from baseline in lesion count at 6 months post-treatment.⁵ In another study, 46 patients with moderate-to-severe AK were treated with the 1,927 nm laser at a higher density (energy, 20 mJ and coverage, >92%) and experienced up to a 95% reduction from baseline in lesion numbers at 6 and 12 months post-treatment.⁶

Combination Treatment With 1,550 nm Erbium-Doped and 1,927 nm Thulium Lasers

Six of the roundtable participants reported using a combination of the 1,550 and 1,927 nm lasers for treatment

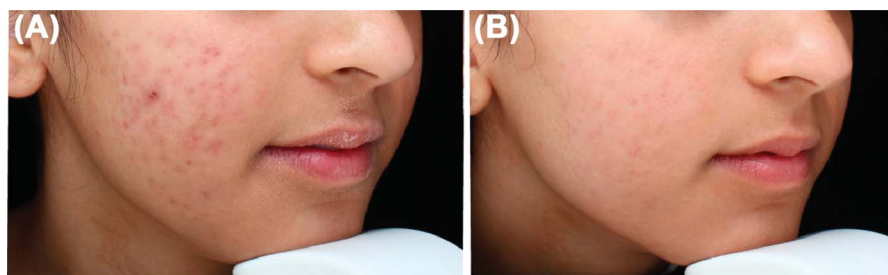


Figure 2. Patient with Fitzpatrick skin type IV and atrophic acne scarring with post-inflammatory erythema at baseline (A) and 4 months post-treatment (B). She received 2 treatment sessions with the 1,550 nm erbium-doped laser (15–25 mJ; treatment level, 5–7). Courtesy of Paul M. Friedman, MD.

TABLE 1. Recommended Treatment Settings for Approved Indications of the 1,550 nm Erbium-Doped and 1,927 nm Thulium Laser System and Treatment Settings for Combination Treatment

Approved Indication	Pulse Energy, mJ	Treatment Level (Coverage, %)		Passes, <i>N</i>	Treatments, <i>N</i>	Treatment Interval, wk	
		FST I-III	FST IV-VI				
1,550 nm wavelength							
General skin resurfacing*							
Facial	35–70	7 (20%)	3–7 (9%–20%)	8	3–5	4–6	
Periorbital area	35–70	7 (20%)	3–6 (9%–17%)	3–4	3–5	4–6	
Nonfacial area	35–70	≤8 (≤23%)	3–6 (9%–17%)	8	3–5	4–6	
1,927 nm wavelength							
Actinic keratosis	20	10 (65%)	1–3 (20%–30%)†	8	3–5	8–12	
Dyschromia	10	10 (50%)	2–5 (25%–40%)	8	2–4	4–8	
Combination of 1,550 nm and 1,927 nm Wavelength							
Combination Use	1,550 nm			1,927 nm			Treatment Interval, Wk
	Pulse Energy, mJ	Treatment Level (Coverage, %)	Passes, <i>N</i>	Pulse Energy, mJ	Treatment Level (Coverage, %)	Passes, <i>N</i>	
General skin resurfacing*							
Facial	25–50	5–8 (14%–23%)	4	10	4–6 (35%–45%)	4	4–6
Nonfacial area	15–45	3–8 (9%–23%)	4–5	10	3–6 (30%–45%)	4	4–6
Traumatic, surgical scars	12–40	4–7 (11%–20%)	8	10	3 (30%)	8	4–6
Striae distensae	30	6 (17%)	4–6	10	3 (30%)	8‡	4–6

* Treatment for pigmented lesions, uneven skin texture, and fine wrinkles.
† For some experts, preferred treatments were topical chemotherapeutics (e.g., topical 5-fluorouracil or retinoids).
‡ Skin cooling between every 2 passes.
FST, Fitzpatrick skin type.

of mild-to-severe photodamage and scars (Table 1). Scars caused by trauma such as burns, including altered skin texture and dyspigmentation due to melanin and hemosiderin, respectively, respond well to a dual laser approach (Table 1).⁷ The 1,550 nm wavelength stimulates collagen remodeling to address scar thickness and texture, and the 1,927 nm wavelength focuses on dyspigmentation associated with scarring.⁸ Case studies have been published on treatment of trauma-related scars using a combination of 1,550 and 1,927 nm lasers.^{8,9}

Investigational Applications

1,550 nm Erbium-Doped Laser

Six of the roundtable participants reported the investigational use of the 1,550 nm laser for Becker nevus, poikiloderma-associated hypopigmentation, postinflammatory erythema, residual hemangioma, traumatic scars, striae rubra, tattoo removal, and wrinkles in any location (Table 2).^{10,11} Participants noted that when treating patients with the Becker nevus, initial hair removal is important and that performing a test spot may guide treatment settings to prevent postinflammatory hyperpigmentation (PIH). There is a greater risk of PIH

for individuals with FST IV to VI, and participants recommended the concomitant use of a topical bleaching agent, sun protection, increased intervals of treatment, and decreased treatment density, as needed, to minimize the risk. Two case series have been published on treatment of the Becker nevus using the 1,550 nm laser.^{12,13}

For treatment of striae rubra with the 1,550 nm laser (Table 2), lesions with recent onset tend to have better outcomes. Initial treatment with a pulsed dye laser, 532 nm laser, or intense pulsed light should be considered to improve erythema and followed by 1,550 nm laser treatment on the same day. A case series of a 12-year-old girl and 13-year-old girl with FST II reported greater than 75% improvement in striae rubra at 6 to 8 weeks post-treatment with the 1,550 nm laser at energy levels ranging from 20 to 70 mJ, delivered over 8 passes (48–168 MTZs/cm² per pass; total, 384–1,344 MTZs/cm²) for 3 to 5 treatments at 4-week intervals.¹⁴ The roundtable recommended combination treatment with the 1,550 and 1,927 nm lasers for striae distensae if brown pigment is present (Table 1). Striae alba should be treated with 1,550 nm alone to address dermal atrophy (pulse energy, 15–30 mJ; treatment level, 5–8 [coverage, 14%–23%]; treatment interval, 4–8 weeks; and minimum of 4–5 treatments), and

TABLE 2. Recommended Treatment Settings for Investigational Applications of the 1,550 nm Erbium-Doped Laser

Application	Pulse Energy, mJ	Treatment Level (Coverage, %)	Passes, N	Treatments, N	Treatment Interval, Wk
Becker's nevus*	8–40	5–10 (14%–29%)	8	5–10	6–8
Hypopigmentation associated with poikiloderma					
Facial	10–20	8 (23%)	8	5†	4–6‡
Nonfacial area	10–20	5 (14%)	8	5†	4–6‡
Postinflammatory erythema	10–25	3–7 (5%–20%)	6–8§	3–5	4–6
Residual hemangioma	20–40	7–10 (20%–29%)	8	3–5	4–6
Scars, traumatic ^{10,11}	40–70	6–13 (17%–38%)	8	5	4
Striae rubra	30	6 (17%)	8	4–6	4–8
Recalcitrant tattoo removal	50	6 (17%)	8	Variable¶	6–8¶
Wrinkles, nonperiorbital location	20–55#	5 (14%)	6–8	≥5†	4–6‡

* Laser hair removal performed on the same day before 1,550 nm laser treatment.
† Initial treatment series followed by a yearly maintenance session.
‡ Treatment interval is 6 to 8 weeks for patients with a history of postinflammatory pigment alteration.
§ Skin cooling between every 2 passes.
|| Recommended adjunct treatment for tattoos with persistent pigment after 10 treatment sessions and those with overlying textural changes or scarring. Laser tattoo removal devices commonly used immediately before the 1,550 nm laser include Q-switch and picosecond lasers. Skin cooling between the different laser modalities is imperative.
¶ Number of treatments dependent on the response per treatment and pigment density.
Pulse energy level dependent on the wrinkle depth.

striae rubra may be treated with pulsed dye laser, potassium-titanyl-phosphate laser, or intense pulsed light, followed by the 1,550 nm laser.

1,927 nm Thulium Laser

Seven of the roundtable participants reported the investigational use of the 1,927 nm laser for a variety of other conditions, including dyschromia, enlarged pores, hypopigmentation associated with poikiloderma, and scars (Table 3). Patients with red and brown dyschromia should be treated initially with visible light technology (e.g., intense pulse light, potassium-titanyl-phosphate laser, or pulse dye laser), followed by the Q-switch laser (755-nm alexandrite; 532-nm double-frequency Nd:YAG) for low-contrast lesions, and then the 1,927 nm thulium laser (Table 1). For patients with hypopigmentation associated with poikiloderma and who have a history of postinflammatory pigment alteration, the treatment interval when using the 1,927 nm laser should be increased to 6 to 8 weeks (Table 3). Treatment of lichen planus pigmentosus, observed in middle-aged patients typically FST IV to VI,¹⁵ can be challenging, as success with topical treatments and oral steroids has been limited.^{16,17} However, treatment with the 1,927 nm laser (Table 3) has shown promising results (Figure 3).

In the management of melasma, it is critical that long-term management strategies be devised. Topical, oral, and laser-based treatments for melasma have targeted photodamage, inflammation, vascularity, and pigmentation. Roundtable participants have observed mixed outcomes in patients with melasma treated with the 1,927 nm laser; therefore, the 1,927

nm laser should not be a first-line melasma treatment. It can exacerbate the condition, particularly during summer, with the use of oral contraceptives and in the absence of pretreatment with a skincare regimen including melanogenesis suppression. Treatment at lower energy and densities should be considered. Topical clobetasol propionate (0.05% cream) was recommended for 1 to 5 days immediately post-treatment, followed by topical treatment alternating tretinoin (0.1% cream) and hydroquinone (4% cream). The roundtable did not recommend using the 1,927 nm laser for melasma in patients with FST V and VI because of an increased risk of disease exacerbation or PIH. Some roundtable participants noted the use of low, intense pulsed light therapy (5–6 J/cm²; vascular and pigmented filters) before treatment (3–4 passes) with the 1,927 nm laser can increase the effectiveness for patients with FST III and IV. Other panelists did not recommend the use of intense pulsed light therapy for patients with melasma.

Two retrospective analyses have been published on treatment with the 1,927 nm laser for melasma.^{18,19} In one study, 100 patients (mean age, 37.8 years [range, 19.0–57.0 years]) with FST II to V underwent 2 treatments with the 1,927 nm laser (9–10 mJ [30%–50% coverage]; delivered over 3 passes) at 4-week intervals.¹⁸ At all time points analyzed (1, 2, and 6 months), the mean Melasma Area and Severity Index (MASI) score was significantly improved (*p* < .005 for all).¹⁸ Three percent of patients experienced PIH, and 2% of patients had recurrence of melasma.¹⁸ In the other study, 20 women (mean age, 41.1 years [range, 30–51

Downloaded from http://journals.lww.com/dermatologicsurgery by BhDM5fEePHKav1Zeuumt1QIN4a+kLhEZgbsIH
04XMI0hCwvCX1AWnYQp/IIQIH3D3D0DORy7TVSFI4C3VC1Y0abggQZXdwmKZBYtws= on 01/30/2024

TABLE 3. Recommended Treatment Settings for Investigational Applications of the 1,927 nm Thulium Laser

Application	Pulse Energy, mJ	Treatment Level (Coverage, %)	Passes, <i>N</i>	Treatments, <i>N</i>	Treatment Interval, Wk
FST I–III					
Actinic keratosis, advanced	10	5–10 (40%–65%)	8	3–5	4–6
Dyschromia					
Lichen planus pigmentosus	5–15	4–5 (35%–40%)	3–4	1–2	4–8
Melasma/PIH	5–10	1–4 (20%–35%)	4–8	1–2	6–12
Enlarged pores	10	3–5 (30%–40%)	8	4–6	4
Hypopigmentation					
Facial	10	4 (35%)	8	6	4
Nonfacial area	10	3 (30%)	8	6	4
Associated with poikiloderma					
Facial	20	7 (50%)	6–8	3–5	4–6
Nonfacial area	20	3–4 (30%–35%)	6–8	3–5	4–6
Scars, hypopigmentation or hyperpigmentation					
Facial*	10	5–7 (40%–50%)	8	5–6	4
Nonfacial area	10	3 (30%)	8	6	4
FST IV–VI					
Hypopigmentation					
Facial	5–10	3 (30%)	8	3–4	4–6

* Total energy for full face, 1.0 to 1.5 mJ; the total energy for small hypopigmented scar, 0.1 mJ.
FST, Fitzpatrick skin type; PIH, postinflammatory hyperpigmentation.

years]) with FST II to IV underwent 1 treatment with the 1,927 nm laser (10 or 20 mJ/cm² [60%–70% coverage]).¹⁹ Patients were advised to initiate treatment with topical hydroquinone 4.0% 1 month after the procedure.¹⁹ At 1 month and 3 to 6 months after laser treatment, the mean MASI score showed significant improvement ($p = .004$ for both) versus baseline; the mean MASI scores continued to improve versus baseline through 6 and 12 months post-treatment ($p = .002$).¹⁹ Overall, 33.3% ($n = 5$) and 13.3% ($n = 2$) of patients reported partial or total reoccurrence of melasma, respectively.¹⁹ Two patients with FST IV experienced PIH that resolved after 3 months with topical bleaching.¹⁹

Best Practices for the Use of the 1,550 nm Erbium-Doped and 1,927 nm Thulium Lasers

Treatment Best Practices

The dermatologic condition, location and size of treatment area, FST, potential for pigmentary or scarring complications,²⁰ and menstrual cycle status affect the total energy that should be applied during a laser treatment. On the face, total energies of 3 to 6 kJ and 1 to 2 kJ are recommended for the 1,550 and 1,927 nm wavelengths, respectively, and are dependent on the facial size and energy per pulse. For the combination laser use, total energies of 1.5 to 2.5 kJ and 0.5 to 1.0 kJ, respectively, are recommended. It is important to match

the treatment depth, which is dependent on the energy applied, to the depth of the scar or wrinkle. The recommended treatment interval for patients with a history of postinflammatory pigment alterations is 6 to 8 weeks for both the 1,550 and 1,927 nm lasers. The risk of PIH in skin of color (FST IV–VI) is associated with the energy and density used. Prevention of bulk heating during laser treatment is important in smaller anatomical areas. Therefore, repeated back and forth motions over a

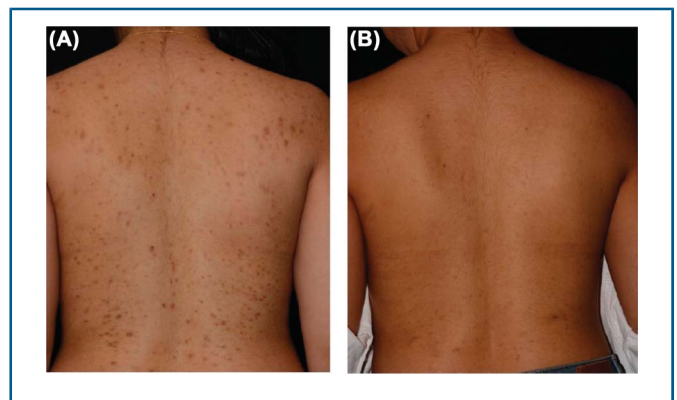

Figure 3. Patient with Fitzpatrick skin type IV and lichen planus pigmentosus at baseline (A) and 3 months post-treatment (B) with the 1,927 nm thulium laser. She received 5 treatment sessions over 19 months (15–20 mJ; treatment level, 5–7; delivered over 8 passes [total kJ, 1.26–1.46]). Courtesy of Jill S. Waibel, MD.

small treatment area should be avoided, and the degree of heating of the treatment area continually evaluated by touching the skin. Application of cold to the treatment area between passes can prevent bulk heating. In addition, the Pro-Nox nitrous oxide system (CareStream Medical International Ltd., Langley, BC, Canada) can be a useful comfort measure for patients during laser treatments at higher settings.

Post-Treatment Best Practices

The recovery time for patients receiving general skin resurfacing can be reduced by delivering less energy in fewer passes with the 1,550 or 1,927 nm lasers, although more treatments are required over a longer timeframe. Post-treatment facial edema can be reduced by the application of cold to the treatment area and elevation of the head at night for 24 to 48 hours or until edema has completely resolved. The application of selective topical creams and serums also can help reduce patient recovery time; recommendations include moisturizers, Alastin Regenerating Skin Nectar (Alastin Skincare, Inc., Carlsbad, CA), cicalfate cream, corticosteroids, diluted vinegar soaks, or antioxidant serum containing 15% L-ascorbic acid, 1% alpha-tocopherol, and 0.5% ferulic acid. For patients with a history of herpes simplex virus, antiviral therapy should be considered. Zinc oxide sunscreen is also recommended to help maintain skin improvement and prevent photodamage. A tinted sunblock is recommended for patients with melasma to protect against visible light exacerbation.

Conclusions

Roundtable discussions confirmed that the 1,550 nm erbium-doped and 1,927 nm thulium dual laser system is effective for a wide range of aesthetic and therapeutic applications, both on and off the face and across all FSTs. Based on years of author experience in the treatment of various dermatologic pathologies with the on-label and investigational use of the dual laser system, recommendations highlight that optimization of treatment settings (e.g., fluence, density, and number of passes) is central to the predictable efficacy and safety outcomes.

References

1. Manstein D, Herron GS, Sink RK, Tanner H, et al. Fractional photothermolysis: a new concept for cutaneous remodeling using microscopic patterns of thermal injury. *Lasers Surg Med* 2004;34:426–38.
2. Fisher GH, Geronemus RG. Short-term side effects of fractional photothermolysis. *Dermatol Surg* 2005;31:1245–9.

3. Jacob CI, Dover JS, Kaminer MS. Acne scarring: a classification system and review of treatment options. *J Am Acad Dermatol* 2001;45:109–17.
4. Chrastil B, Glaich AS, Goldberg LH, Friedman PM. Second-generation 1,550-nm fractional photothermolysis for the treatment of acne scars. *Dermatol Surg* 2008;34:1327–32.
5. Weiss ET, Brauer JA, Anolik R, Reddy KK, et al. 1927 nm fractional resurfacing of facial actinic keratoses: a promising new therapeutic option. *J Am Acad Dermatol* 2013;68:98–102.
6. Lim DS. High-density 1927 thulium laser for actinic keratosis – is this the ideal field treatment? Presented at: Australasian College of Dermatologists 48th Annual Scientific Meeting; May 16, 2015, 2015; Adelaide, Australia.
7. Issler-Fisher AC, Waibel JS, Donelan MB. Laser modulation of hypertrophic scars: technique and practice. *Clin Plast Surg* 2017;44:757–66.
8. Tao J, Champlain A, Weddington C, Moy L, et al. Treatment of burn scars in Fitzpatrick phototype III patients with a combination of pulsed dye laser and non-ablative fractional resurfacing 1550 nm erbium: glass/1927 nm thulium laser devices. *Scars Burn Heal* 2018;4:2059513118758510.
9. Finney R, Torbeck R, Saedi N, Glaich AS, Goldberg LH, Dai T, Kunishige. Non-ablative fractional resurfacing in the treatment of scar contracture. *Lasers Surg Med* 2016;48:170–3.
10. Kauvar ANB, Kubicki SL, Suggs AK, Friedman PM. Laser therapy of traumatic and surgical scars and an algorithm for their treatment. *Lasers Surg Med* 2020;52:125–136.
11. Waibel J, Wulkan AJ, Lupo M, Beer K, et al. Treatment of burn scars with the 1,550 nm nonablative fractional erbium laser. *Lasers Surg Med* 2012;44:441–6.
12. Glaich AS, Goldberg LH, Dai T, Kunishige JH, et al. Fractional resurfacing: a new therapeutic modality for Becker's nevus. *Arch Dermatol* 2007;143:1488–90.
13. Balaraman B, Friedman PM. Hypertrichotic Becker's nevi treated with combination 1,550 nm non-ablative fractional photothermolysis and laser hair removal. *Lasers Surg Med* 2016;48:350–3.
14. Katz TM, Goldberg LH, Friedman PM. Nonablative fractional photothermolysis for the treatment of striae rubra. *Dermatol Surg* 2009;35:1430–3.
15. Robles-Méndez JC, Rizo-Frías P, Herz-Ruelas ME, Pandya AG, et al. Lichen planus pigmentosus and its variants: review and update. *Int J Dermatol* 2018;57:505–14.
16. Muthu SK, Narang T, Saikia UN, Kanwar AJ, et al. Low-dose oral isotretinoin therapy in lichen planus pigmentosus: an open-label non-randomized prospective pilot study. *Int J Dermatol* 2016;55:1048–54.
17. Al-Mutairi N, El-Khalawany M. Clinicopathological characteristics of lichen planus pigmentosus and its response to tacrolimus ointment: an open label, non-randomized, prospective study. *J Eur Acad Dermatol Venereol* 2010;24:535–40.
18. Kurmuş G, Tatlıparmak A, Aksoy B, Koç E, et al. Efficacy and safety of 1927 nm fractional thulium fiber laser for the treatment of melasma: a retrospective study of 100 patients. *J Cosmet Laser Ther* 2019;21:408–11.
19. Niwa Massaki ABM, Eimpunth S, Fabi SG, Guiha I, et al. Treatment of melasma with the 1,927-nm fractional thulium fiber laser: a retrospective analysis of 20 cases with long-term follow-up. *Lasers Surg Med* 2013;45:95–101.
20. Roberts WE. Skin type classification systems old and new. *Dermatol Clin* 2009;27:529–33, viii.